



## ■ PROSTHODONTICS

# All-on-four rehabilitation using photogrammetric impression technique

Andrés Sánchez-Monescillo, DDS, MS, PhD/Jaime Hernanz-Martín, DDS/Carlos González-Serrano, DDS, MS/  
José González-Serrano, DDS, MS/Sillas Duarte Jr, DDS, MS, PhD

Conventional implant impression techniques may introduce distortions in the framework that can lead to a lack of accuracy of the prostheses. Misfit between the restoration and the implants facilitates the occurrence of biomechanical failures and prostheses complications due to inadequate stress dissipation. Digital impressions present an alternative to eliminate procedural distortions by improving the fit between the restoration and the implants. Among the different types of digital impressions, photogrammetry has emerged as an alternative

for multiple implant impressions. This case report describes photogrammetric technique for a full-arch rehabilitation in All-on-four of a 68-year-old patient with a fixed implant-supported restoration on the mandible. Photogrammetric technique has demonstrated to be a successful digital alternative to conventional multiple-implant impression. Esthetics and function remained stable over a follow-up period of 1 year. No biomechanical or biologic complications were observed. (*Quintessence Int* 2019;50:288–293; doi: 10.3290/j.qi.a42098)

**Key words:** All-on-four, digital impression, implant impression, photogrammetric impression, photogrammetry, stereophotogrammetric impression

Passive fit of implant restoration remains one of the most challenging aspects of implant dentistry.<sup>1</sup> Passive fit has been defined as “the optimum fit of superstructures to abutments that determines the absence of bone tension without the occlusal loading,” and is considered a crucial factor for the long-term success of dental implant restorations.<sup>1,2</sup> Commonly, it is accepted that passive fit relates to the gap between the implant or the abutment and the framework. However, there is no agreement in the literature regarding an acceptable gap width, which might range between 10 and 150  $\mu\text{m}$ .<sup>1,3</sup> Thus, passive fit can be considered as the minimum gap that permits a framework connection without causing strain.<sup>1,2</sup>

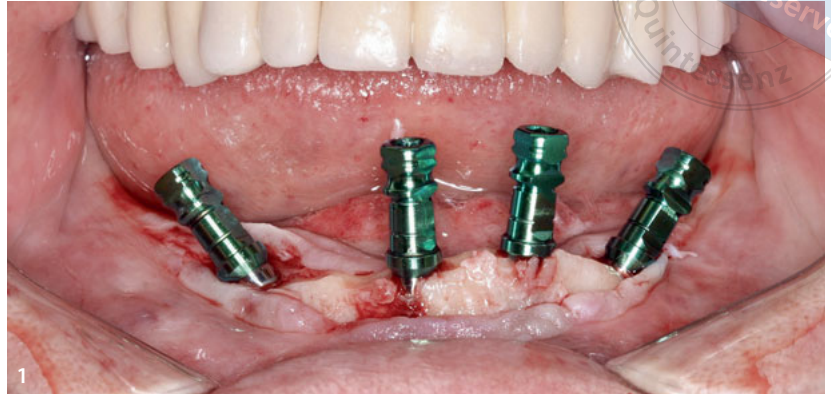
Achieving an accurate fit of the implant-supported prosthesis improves the long-term prognosis of the rehabilitations.<sup>1-5</sup> The absence of a precise fit yields biomechanical failures such as framework distortion or ceramic detachment due to inadequate stress dissipation.<sup>6-9</sup> A lack of fit between the framework and implants can be attributed to distortions occurring during

the impression taking or cast fabrication.<sup>2</sup> Therefore, in order to reduce distortions of traditional impression techniques, the use of digital technology has been proposed.<sup>3,10,11</sup>

The introduction of digital impressions led to the improvement of the conventional workflow, increasing accuracy and simplicity of the technique.<sup>2</sup> Digital impressions reduce the time in data gathering for the fabrication of the prosthesis and eliminate some of the laboratory costs.<sup>12-14</sup> Computer-aided design/computer-assisted manufacturing (CAD/CAM) allows for digital acquisition of data and facilitates the laborious rehabilitation steps and procedures, offering appropriate esthetics, reproducibility, and functional outcomes due to the improved accuracy of the prosthetic restoration.<sup>15-17</sup> CAD/CAM techniques incorporate these two elements, the impression for the data acquisition and the manufacturing process or fabrication of the prosthesis.

Photogrammetry is a digital data gathering alternative to conventional impressions that might improve the final precision of the framework.<sup>18,19</sup> Photogrammetry is considered the

**Fig 1** Implant placement. Four implants were placed with All-on-4 technique.



**Fig 2** PICcamera. This stereocamera identifies the PICabutment in its 3D position.



science of making measurements from photographs.<sup>19-21</sup> Thus, this technique can determine the geometric properties of objects and their spatial arrangement and can be obtained from two-dimensional (2D) and/or three-dimensional (3D) photographic images via metric information.

These 3D images reveal the direction vector from one point to another and its exact distance. The most important characteristic is the precision with which non-contacting objects are measured.<sup>19,21</sup> Photogrammetry has been employed to study the shape and position of teeth and both dental arches.<sup>19</sup> In orthodontics, it allows the analysis of 3D variations of the palate and assessment of tooth movement.<sup>22-25</sup> Moreover, this technique has been used to verify the accuracy of other implant impression techniques.<sup>19,21,26</sup>

Although photogrammetry has been proposed as an alternative to conventional impressions, slow progress has been made in the field of implantology for the application of this technique.<sup>11,19,26</sup> Recently, case reports using photogrammetry

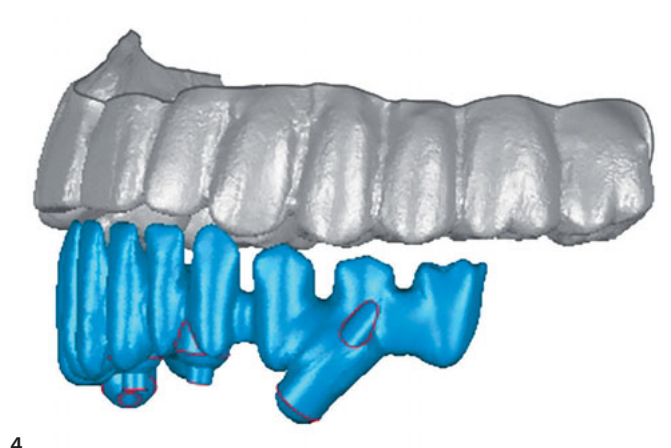
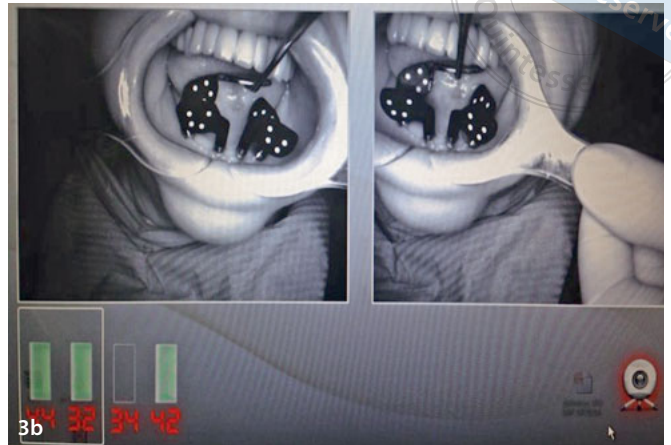
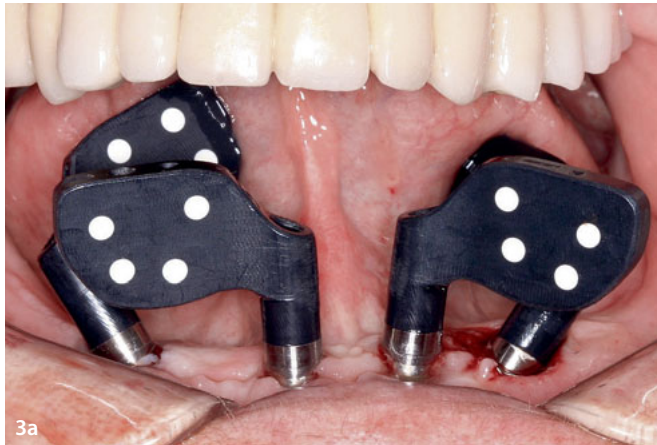
have been reported with promising results.<sup>5,27</sup> However, to the best of our knowledge, this technique has not been reported for All-on-4 rehabilitation.

### Case presentation

A 68-year-old woman with no relevant medical history requested an improvement in her oral situation. Intraoral examination revealed a metal-ceramic fixed implant restoration in the maxilla and an edentulous mandible. Radiographic examination (panoramic radiography and computed tomography) and analysis of articulated diagnostic casts were performed. Treatment planning consisted of four implants and All-on-4 prosthetic restorations through photogrammetric implant impression technique (PIC Dental).

Diagnostic wax try-in denture and the antagonist arch cast poured in stone were scanned extraorally (D710 3D Scanner; 3Shape). This information established the first STL file.

copyright by  
all rights reserved



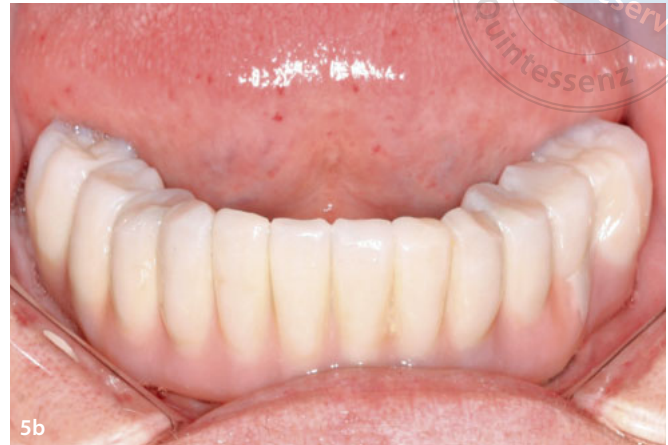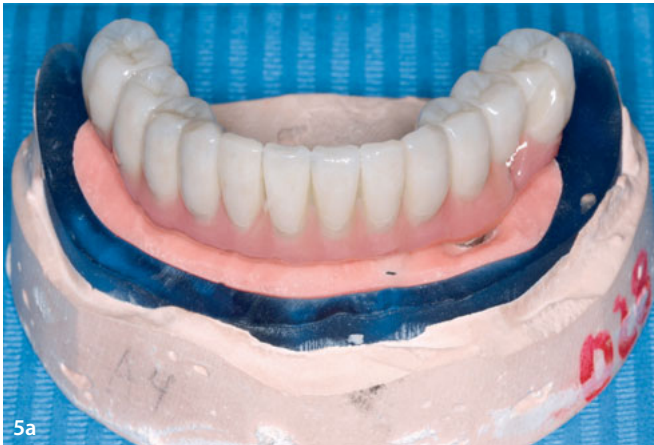**Figs 3a to 3c** (a) PICabutment placement. Specially coded black-flag-shaped abutments are screwed onto the implants for obtaining the metric information of the implant position. (b) PICcamera capture. PICcamera captures the position of the implants in order to obtain the PICfile. (c) PICfile. STL file formed with information of implant position and angulation.

**Fig 4** STL of prosthetic design. Final digital file obtained through the integration of the three STL files (prosthetic design, PICfile, and tissue status after surgery).

Bilateral inferior alveolar nerve, lingual nerve, and buccal nerve block were administered using articaine in a 4% solution with epinephrine 1:100,000 (Ultracain, Normon). A full-thickness flap was raised and osseous recontouring of the alveolar ridge was performed. A total of four Zimmer TSV (Zimmer Dental) implants in All-on-4 technique were placed: two 3.7 × 13 mm implants in positions of the mandibular left second premolar (tooth 35 according to FDI notation), left lateral incisor (position 32), one 3.3 × 13 mm implant in right lateral incisor (position 42), and one 3.3 × 10 mm in right second premolar (position 45). Implants in positions 32 and 42 were placed parallel and 35 and 45 were placed with a 30-degree angulation (Fig 1). Implant stability quotient (ISQ) value given by an Osstell instrument (Oss-

tell) was assessed to assure the primary stability of each implant. The Osstell is based on the resonance frequency analysis that determines if an implant presents sufficient (primary) stability in the bone. The patient was sutured with 4/0 silk and the sutures were removed 7 days after surgery. The second phase was carried out after 2 months of osseointegration. Healing abutments 5 mm in length (Zimmer, Zimmer Dental) were screwed onto the implants.

A digital implant impression using the photogrammetric technique was performed after 1 week of healing. For this purpose, a specialized 3D stereo camera (PICcamera, PIC Dental) (Fig 2) was used to record the position of dental implants intra-orally using the photogrammetric impression technique. The



**Figs 5a and 5b** (a) Final restoration. Final hybrid prosthesis on the stereolithographic model. (b) Final restoration. Final hybrid prosthesis placed in the patient's mouth.

camera has two CCD (charge-coupled device) sensors that record 3D position and geometry of the implants through the identification of special black flag-shaped screw-retained abutments individually coded (PICabutments, PIC Dental) that were placed onto the implants (Fig 3a).

The PICcamera captured more than 60 images every 20 seconds, obtaining the second STL file (PICfile, PIC Dental) with the information of the implants (Figs 3b and 3c). Subsequently, PICabutments devices were unscrewed and healing abutments were screwed back onto the implants.

An alginate impression was made, poured and digitally scanned (D710 3D Scanner; 3Shape) to obtain the third STL file with the basic topography information of the soft tissues. The three STL files were integrated using an algorithm for finding the best-fit line (Fig 4). The digital information obtained was sent to the CAM milling center where a stereolithographic model was manufactured using a 3D printer (Eden250, Objet) and the prosthesis was fabricated using a cobalt-chromium (Co-Cr) framework (Fig 5a).

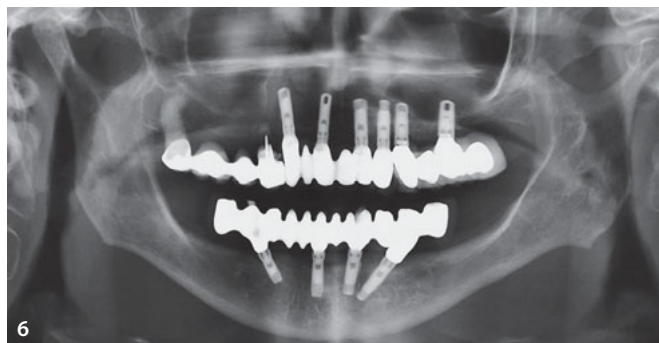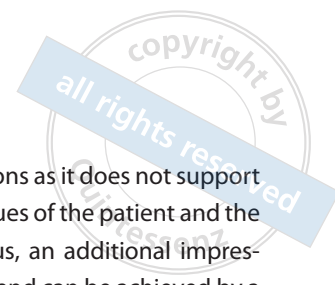
The passive fit of the structure was checked by the test of the single screw, screw resistance test, and assessed with periapical radiographs. Finally, the Co-Cr structure was sent to the dental laboratory to incorporate the acrylic resin teeth to the framework in a resin matrix. Final restoration was placed and an adequate occlusion was achieved (Fig 5b). Clinical and radiographic follow-up after 1 year showed an accurate fit of the restoration and a favorable evolution of the implants with a

slight bone loosening in the implant placed in the mandibular right central incisor position (41) (Fig 6). No implant screw loosening or mechanical or biologic complications were observed at the 1-year follow-up.

## Discussion

Encompassed within CAD/CAM technology, photogrammetry has been used in other fields for mapping applications and the civil engineering industry<sup>20,21</sup> and also in the world of medicine. There are many studies that support the use of this technology for implant prostheses with in-vitro studies, in which the passive fit obtained with this method is assessed and compared with other digital solutions and conventional techniques, showing similar results.<sup>3,20,21</sup> Photogrammetry overcomes some of the limitations of other digital and conventional impressions when a large number of implants, long distances between implants, and different implant angulations are presented.<sup>14</sup>

Photogrammetry allows the design of accurate implant-supported structures.<sup>18</sup> Furthermore, this technique facilitates impression taking and increases the speed of the production of the prosthesis, reducing working time and increasing patient and dental practitioner satisfaction.<sup>5,18</sup> Photogrammetry usually displays the exact position of all the implants with better accuracy than other procedures.<sup>5,21,27</sup> Several authors<sup>6-9,19</sup> concluded that the lack of fit may be a significant factor for compli-



**Fig 6** Panoramic radiograph: 1-year follow-up.

cations and may affect the transfer of stress between the prosthesis and the implant. It seems that much remains to be learned about this complex interface.<sup>13</sup> Tension-free connections and passive fit between implants and the prosthetic structures are essential for the medium- and long-term success of implant-supported rehabilitations.<sup>4,5</sup>

Photogrammetry eludes the use of impression abutments, implant body casts, scan bodies, trays, and conventional impression materials.<sup>5,27</sup> Nevertheless, based on current tech-

nology, photogrammetry has limitations as it does not support the reproduction of soft and hard tissues of the patient and the implant position simultaneously. Thus, an additional impression with this information is required and can be achieved by a digital intraoral or extraoral impression through the conventional impression or the poured cast. ■

## Conclusion

As this case describes, the use of photogrammetry as an alternative to digital impression for multiple implants is an easy and reliable technique that allows an adequate fit and no prosthetic complications. Although it offers several advantages over conventional impressions and other digital impressions, photogrammetric technique does not reproduce the information for the soft and hard tissue. Therefore, an additional impression for this purpose is needed. Further clinical and in-vitro studies are needed to validate the benefits of this technique for implant-supported prosthesis.


## Declaration

The authors declare that no conflict of interest exists.

## References

- Oyagüe RC, Sánchez-Turrión A, López-Lozano JF, Suárez García MJ. Vertical discrepancy and microleakage of laser-sintered and vacuum-cast implant-supported structures luted with different cement types. *J Dent* 2012;40:123–130.
- Oyagüe RC, Sánchez-Jorge MI, Sánchez Turrión A. Evaluation of fit of zirconia posterior bridge structures constructed with different scanning methods and preparation angles. *Odontology* 2010;98:170–172.
- Lee H, So JS, Hochstedler JL, Ercoli C. The accuracy of implant impressions: a systematic review. *J Prosthet Dent* 2008;100:285–291.
- Heckmann SM, Karl M, Wichmann MG, Winter W, Graef F, Taylor TD. Cement fixation and screw retention: parameters of passive fit. An in vitro study of three-unit implant-supported fixed partial dentures. *Clin Oral Implants Res* 2004;15:466–473.
- Sánchez-Monescillo A, Sánchez-Turrión A, Vellon-Domarco E, Salinas-Goodier C, Prados-Frutos JC. Photogrammetry impression technique: a case history report. *Int J Prosthodont* 2016;29:71–73.
- Jemt T, Rubenstein JE, Carlsson L, Lang BR. Measuring fit at the implant prosthodontic interface. *J Prosthet Dent* 1996;75:314–325.
- Jemt T, Lie A. Accuracy of implant-supported prostheses in the edentulous jaw. Analysis of precision of fit between cast gold-alloy frameworks and master casts by means of a three-dimensional photogrammetric technique. *Clin Oral Implants Res* 1995;6:172–180.
- Jemt T. Three-dimensional distortion of gold alloy castings and welded titanium frameworks. Measurements of the precision of fit between completed implant prostheses and the master casts in routine edentulous situations. *J Oral Rehabilitation* 1995;22:557–564.
- Jemt T, Book K, Lie A, Börjesson T. Mucosal topography around implants in edentulous upper jaws. Photogrammetric three-dimensional measurements of the effect of replacement of a removable prosthesis with a fixed prosthesis. *Clin Oral Implants Res* 1994;5:220–228.
- Al-Fadda SA, Zarb GA, Finer Y. A comparison of the accuracy of fit of 2 methods for fabricating implant-prosthodontic frameworks. *Int J Prosthodont* 2007;20:125–131.
- Ortorp A, Jemt T, Bäck T, Jälevik T. Comparison of precision of fit between cast and CNC-milled titanium implant frameworks for the edentulous mandible. *Int J Prosthodont* 2003;16:194–200.
- Beuer F, Schweiger J, Edelhoff D. Digital dentistry: an overview of recent developments for CAD/CAM generated restorations. *Br Dent J* 2008;204:505–511.
- Rubenstein JE, Ma T. Comparison of interface relationships between implant components for laser-welded titanium frameworks and standard cast frameworks. *Int J Oral Maxillofac Implants* 1999;14:491–495.
- Alsharbaty MHM, Alikhasi M, Zarrati S, Shamshiri AR. A clinical comparative study of 3-dimensional accuracy between digital and conventional implant impression techniques (epub ahead of print, 9 Feb 2018). *J Prosthodont* doi: 10.1111/jopr.12764.

- 15.** Güth JF, Almeida E Silva JS, Beuer FF, Edelhoff D. Enhancing the predictability of complex rehabilitation with a removable CAD/CAM-fabricated long-term provisional prosthesis: a clinical report. *J Prosthet Dent* 2012;107:1–6.
- 16.** Bentz RM, Balshi SF. Complete oral rehabilitation with implants using CAD/CAM technology, stereolithography, and conoscopic holography. *Implant Dent* 2012;21:8–12.
- 17.** Rubio Serrano M, Albalat Estela S, Peñarrocha Diago M, Peñarrocha Diago M. Software applied to oral implantology: update. *Med Oral Patol Oral Cir Bucal* 2008;13:661–665.
- 18.** Peñarrocha-Diago M, Balaguer-Martí JC, Peñarrocha-Oltra D, Balaguer-Martínez JF, Peñarrocha-Diago M, Agustín-Panadero R. A combined digital and stereophotogrammetric technique for rehabilitation with immediate loading of complete-arch, implant-supported prostheses: a randomized controlled pilot clinical trial. *J Prosthet Dent* 2017;118:596–603.
- 19.** Jemt T, Bäck T, Petersson A. Precision of CNC-milled titanium frameworks for implant treatment in the edentulous jaw. *Int J Prosthodont* 1999;12:209–215.
- 20.** Bergin JM, Rubenstein JE, Mancl L, Brudvik JS, Raigrodski AJ. An in vitro comparison of photogrammetric and conventional complete-arch implant impression techniques. *J Prosthet Dent* 2013;110:243–251.
- 21.** Bratos M, Bergin JM, Rubenstein JE, Sorensen JA. Effect of simulated intraoral variables on the accuracy of photogrammetric imaging technique for complete-arch implant prostheses. *J Prosthet Dent* 2018;120:232–241.
- 22.** Goellner M, Schmitt J, Karl M, Wichmann M, Holst S. Photogrammetric measurement of initial tooth displacement under tensile force. *Med Eng Phys* 2010;32:883–888.
- 23.** Kau CH, Kamel SG, Wilson J, Wong ME. New method for analysis of facial growth in a pediatric reconstructed mandible. *Am J Orthod Dentofacial Orthop* 2011;139:285–290.
- 24.** Deli R, Gioia E Di, Galantucci LM, Percoco G. Accurate facial morphologic measurements using a 3-camera photogrammetric method. *J Craniofac Surg* 2011;22:54–59.
- 25.** Marini I, Bonetti GA, Achilli V, Salemi G. A photogrammetric technique for the analysis of palatal three-dimensional changes during rapid maxillary expansion. *Eur J Orthod* 2007;29:26–30.
- 26.** Ortorp A, Jemt T, Bäck T. Photogrammetry and conventional impressions for recording implant positions: a comparative laboratory study. *Clin Implant Dent Relat Res* 2005;7:43–50.
- 27.** Gómez-Polo M, Gómez-Polo C, Del Río J, Ortega R. Stereophotogrammetric impression making for polyoxymethylene, milled immediate partial fixed dental prostheses. *J Prosthet Dent* 2018;119:506–510.



**Andrés Sánchez-Monescillo**

**Andrés Sánchez-Monescillo** Visiting Assistant Professor, Advanced Program in Operative and Adhesive Dentistry, Herman Ostrow School of Dentistry, University of Southern California, Los Angeles, California, USA.

**Jaime Hernanz-Martín** Assistant Professor, Advanced Program in Implantology, Surgery and Peri-Implantology, Alfonso X el Sabio University of Madrid, Madrid, Spain.

**Carlos González-Serrano** Assistant Professor, School of Medicine, Department of Dentistry, CEU San Pablo University, Boadilla del Monte, Madrid, Spain.

**José González-Serrano** Honorary Collaborating Professor, Department of Dental Clinical Specialities, School of Dentistry, Complutense University of Madrid, Madrid, Spain.

**Sillas Duarte Jr** Associate Professor and Chair, Division of Restorative Sciences, Ostrow School of Dentistry, University of Southern California; and Director, Advanced Program in Operative Dentistry, University of Southern California, Los Angeles, California, USA.

**Correspondence:** Dr Andrés Sánchez-Monescillo, Norris Dental Science Center, 925 W 34th Street, DEN 311 Los Angeles, California 90089-0641, USA. Email: asanchezmonescillo@gmail.com