

Photogrammetry Impression Technique: A Case History Report

Andrés Sánchez-Monescillo, DSD, MSc, PhD¹/Andrés Sánchez-Turrión, MD, DDS, PhD²/

Elena Vellon-Domarco, DDS³/Carmen Salinas-Goodier, DDS, MSc¹/Juan Carlos Prados-Frutos, MD, DDS, PhD¹

Purpose: The aim of this report is to present photogrammetry as a reliable step in the fabrication of a full-arch immediate rehabilitation. **Materials and Methods:** A 59-year-old man attended the department seeking dental rehabilitation for the sequelae of severe oral health neglect. The mandibular teeth suffered from advanced periodontal disease and the patient wore a maxillary complete denture. An irreversible hydrocolloid impression of the mandibular arch was made, poured in stone, and digitally scanned to create the first stereolithography (STL) file. All teeth with the exception of two retained as landmarks were extracted, and seven implants were placed under local anesthesia and their positions recorded using photogrammetry. Maxillary and mandibular dental arch alginate impressions were made, poured in laboratory stone, and scanned. A provisional restoration was placed 7 hours after surgery using the STL files to determine the best-fit line. **Results:** Radiographic and clinical follow-up after 1 year showed a favorable evolution of the implants. No screw loosening or other mechanical or biologic complications were observed. **Conclusion:** The case history using the described system suggests certain advantages over conventional techniques. More research is needed to assess the possible benefits associated with photogrammetry when making implant-supported restorations. *Int J Prosthodont* 2016;29:71–73. doi: 10.11607/ijp.4287

Photogrammetry is currently proposed as an alternative to conventional implant impression techniques. It is based on the determination of geometric properties of objects and their spatial arrangement and obtained via metric information from two-dimensional (2D) and/or three-dimensional (3D) photographic images. The latter can be used to ascertain the direction vector and exact distance from one point to another. The most important characteristic of photogrammetry is the precision with which it measures noncontacting objects.

PIC Camera (PIC Dental) is a stereo camera that records the position of dental implants by means of photogrammetry. It consists of two charge-coupled device (CCD) cameras specially designed for clinical use that determine the 3D geometry and positions of the implants through the identification of special flag-shaped screwed abutments with individual coding (PIC Abutment, PIC Dental).

The aim of this report is to present photogrammetry as a reliable step in the fabrication of a full-arch immediate rehabilitation.

Case History

A 59-year-old systemically healthy man attended the Department of Stomatology at Rey Juan Carlos University (Madrid, Spain) seeking dental rehabilitation for the sequelae of severe oral health neglect (Fig 1a). The mandibular teeth suffered from advanced periodontal disease, and the patient wore a maxillary complete denture. Radiographic examination (panoramic radiography and computed tomography)

¹Faculty, Department of Stomatology, Rey Juan Carlos University, Madrid, Spain.

²Professor, Department of Stomatology, Complutense University, Madrid, Spain.

³Private Practice, Ciudad Real, Spain.

Correspondence to: Dr Juan Carlos Prados-Frutos.

Email: juancarlos.prados@urjc.es

©2016 by Quintessence Publishing Co Inc.

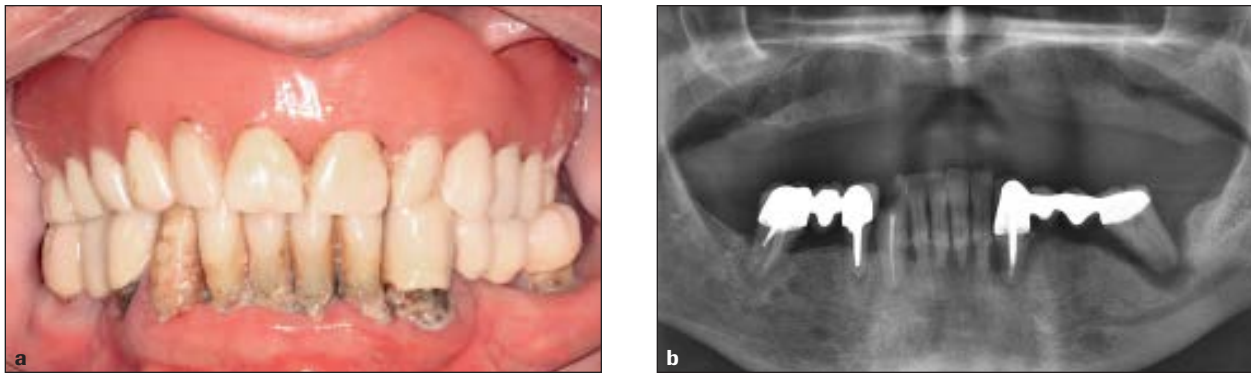


Fig 1 (a) Initial clinical situation and (b) preoperative panoramic radiography.

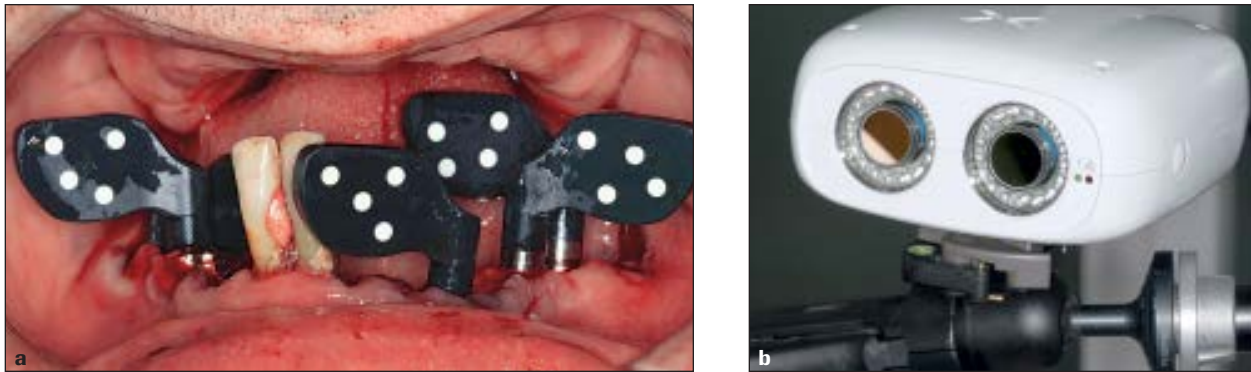


Fig 2 (a) PIC Abutment devices on implants. Remaining teeth are used as landmarks. (b) PIC Camera. This device uses photogrammetry technology for recording the position of dental implants.

(Fig 1b) and analysis of articulated diagnostic casts were performed. The patient signed an informed consent that explained the proposed treatment protocol that would be undertaken.

An irreversible hydrocolloid impression of the mandibular arch was made, poured in stone, and digitally scanned extraorally (D710 3D Scanner, 3Shape). The scan information constituted the first stereolithography (STL) file. Bilateral inferior alveolar nerve, lingual nerve, and buccal nerve block were achieved using articaine in a 4% solution with epinephrine 1:100,000 (Artinibsa, Inibsa). A full-thickness flap was raised and all teeth with the exception of the mandibular right central incisor and the mandibular right lateral incisor were extracted. These two teeth were retained for use as landmarks and to overlap the first and second STL file, as PIC Dental recommends. A total of seven Zimmer TSV (Zimmer Dental) implants were placed under local anesthesia. An implant stability quotient

(ISQ) reading was made to record the initial stability of each implant.

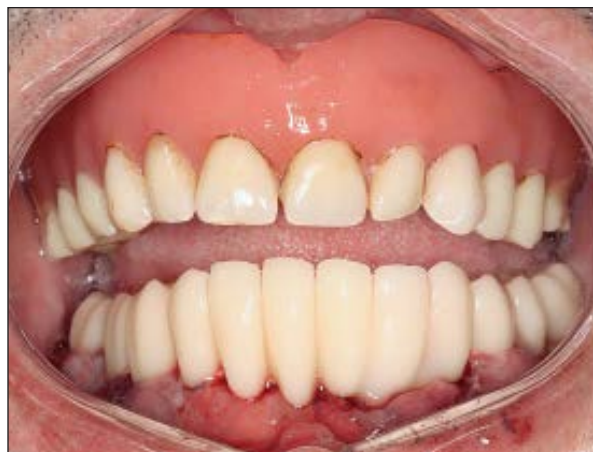Personal patient data was registered in the PIC Dental software, followed by the positions and technical data of the implants, that were input into the program. PIC Abutments were screwed into the implants (Fig 2a) and PIC Camera (Fig 2b) took more than 60 pictures every 20 seconds, creating the second STL file (PIC File) with the information on the implants. The remaining teeth were then extracted.

Maxillary and mandibular dental arch alginate impressions were made, poured in laboratory stone, and digitally scanned (D710 3D Scanner, 3Shape) which enabled a third STL file with basic topographic information of the soft tissues. The PIC File the STL files obtained from the digital impressions of the soft tissues were integrated using an algorithm for finding the best-fit line (Fig 3). A provisional restoration was placed 7 hours after surgery (Fig 4).



Fig 3 (above) PIC File showing implant position and angulation in relation to the prosthesis.

Fig 4 (right) Provisional immediate restoration placement.



Radiographic and clinical follow-up after 1 year showed a favorable evolution of the implants. No screw loosening or other mechanical or biologic complications were seen throughout this preliminary observation period.

Discussion

Photogrammetric techniques facilitate implant impression making and reduce manufacturing time for the prosthesis while permitting an accurate design of the implant-supported components. Jemt et al¹ suggested that an imperfect framework fit may be a significant complicating factor affecting transfer of stress between prosthesis and implants. Digital impressions reduce inaccuracies caused by conventional impressions and provide more accurate adjustment.^{2,3} Photogrammetry also reduces costs related to the impression and provisional prosthesis materials as well as clinical and laboratory fabrication time, while minimizing tissue manipulation.⁴ However, photogrammetry does not simultaneously reproduce soft and hard tissues and implant position, increasing the complexity of the subsequent manufacturing stages.⁵

Conclusion

The description of a specific case history using the described novel system suggests certain advantages over conventional techniques. More studies are necessary to ensure rigorous scientific support and to truly assess the possible benefits associated with the adjustment and reliability of photogrammetry in making implant-supported restorations.

Acknowledgments

The authors reported no conflicts of interest related to this study.

References

1. Jemt T, Bäck T, Petersson A. Photogrammetry—An alternative to conventional impressions in implant dentistry? A clinical pilot study. *Int J Prosthodont* 1999;12:363–368.
2. Oyagüe RC, Sánchez-Jorge MI, Sánchez Turrión A. Evaluation of fit of zirconia posterior bridge structures constructed with different scanning methods and preparation angles. *Odontology* 2010;98:170–172.
3. Rubenstein JE, Ma T. Comparison of interface relationships between implant components for laser-welded titanium frameworks and standard cast frameworks. *Int J Oral Maxillofac Implants* 1999;14:491–495.
4. Pradies G, Ferreiroa A, Özcan M, Giménez B, Martínez-Rus F. Using stereophotogrammetric technology for obtaining intra-oral digital impressions of implants. *J Am Dent Assoc* 2014; 145:338–344.
5. Peñarrocha-Oltra D, Agustín-Panadero R, Bagán L, Giménez B, Peñarrocha M. Impression of multiple implants using photogrammetry: Description of technique and case presentation. *Med Oral Patol Oral Cir Bucal* 2014;19:e366–e371.